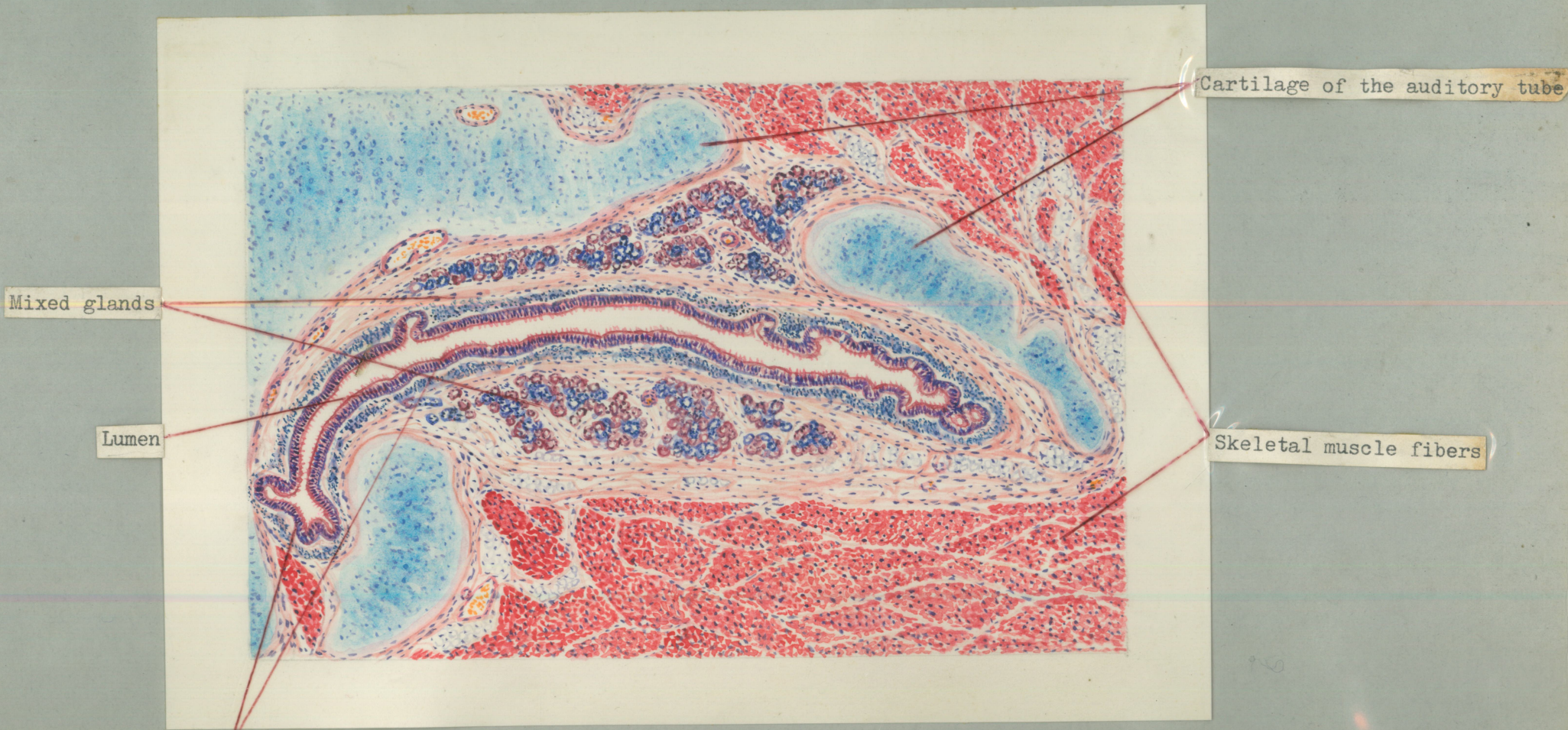


NUM-Lp002-239

Auditory tube, human. HX-E.



Mixed glands

Lumen

Cartilage of the auditory tube

Skeletal muscle fibers

Pseudostratified ciliated columnar epithelium

耳管 (人)

HX-E 染色

x 30

6