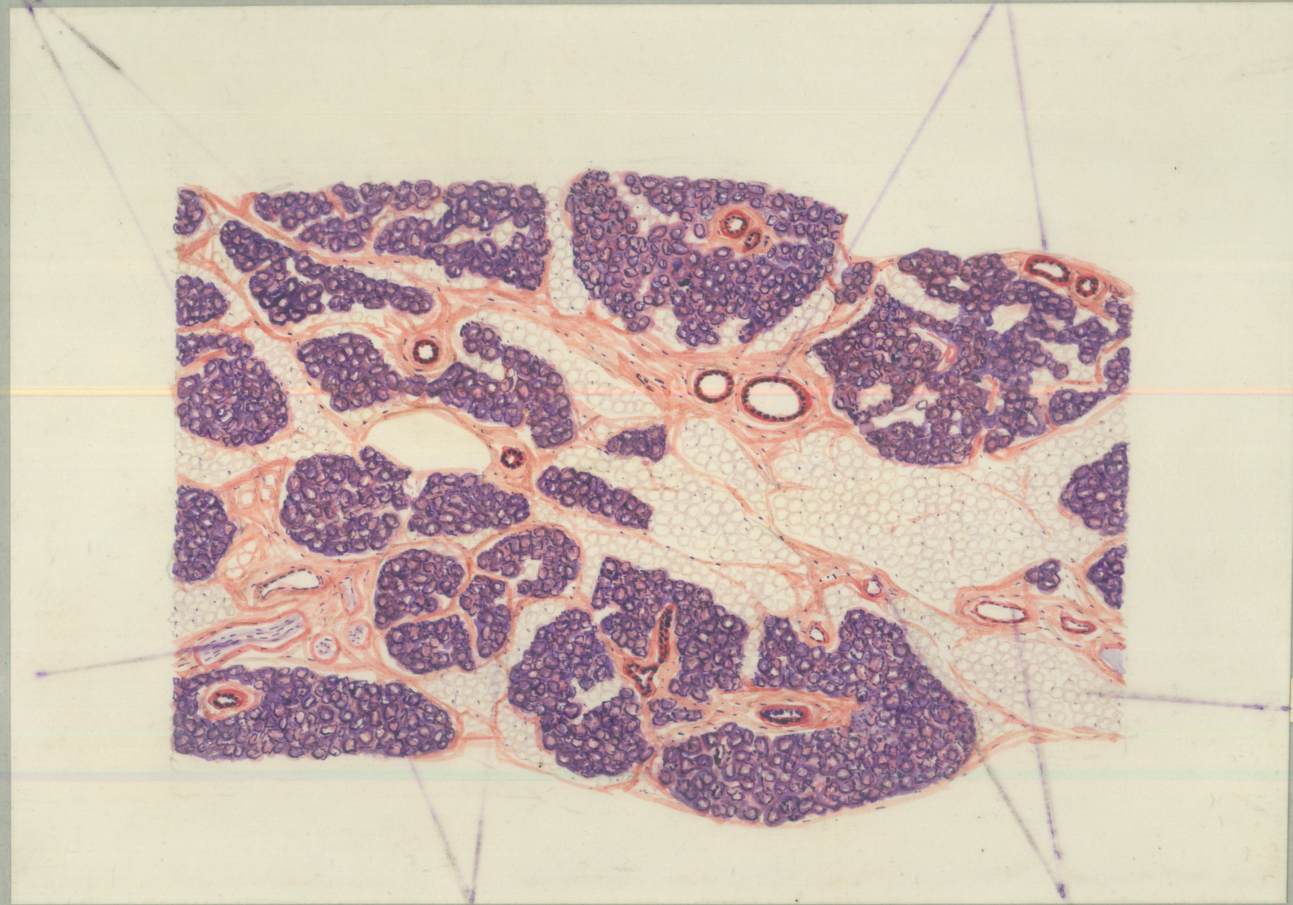


NUM-Lp002-236

Lacrimal gland, human, HX-E.

Interlobular connective tissue

Excretory ducts



Nerve fibers

Fat tissue

Terminal portion

Blood vessels

淚腺 (人) HX-E 染色 x 20 3