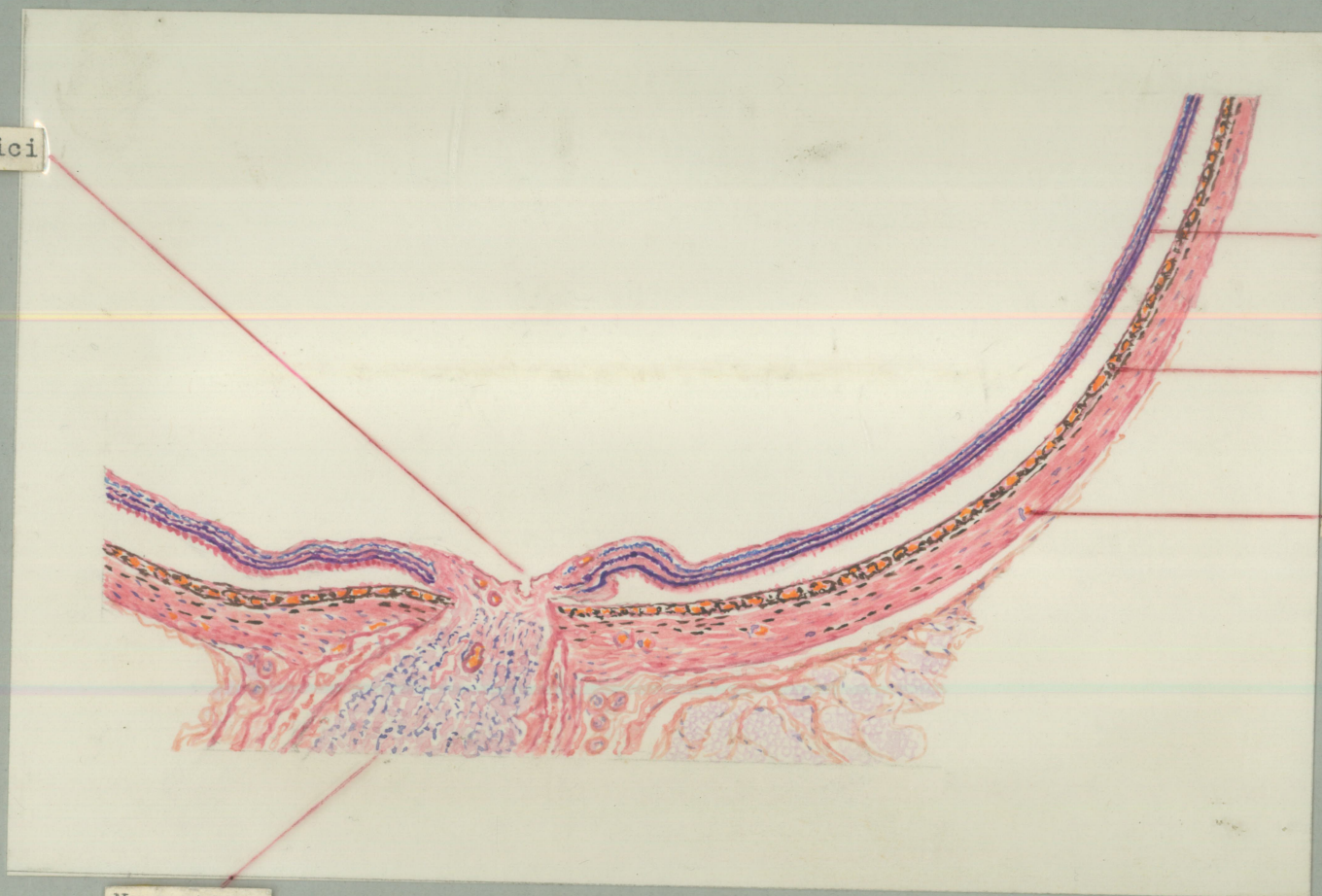


NUM-Lp002-232

Posterior portion of eye-ball, human. HX-E. (horizontal section)

Excavatio papillae n. optici



Detached retina

Chorioidea

Sclera

N. opticus

眼球後部 (人) HX-E 染色

x 10

z