

NUM-Lp002-231

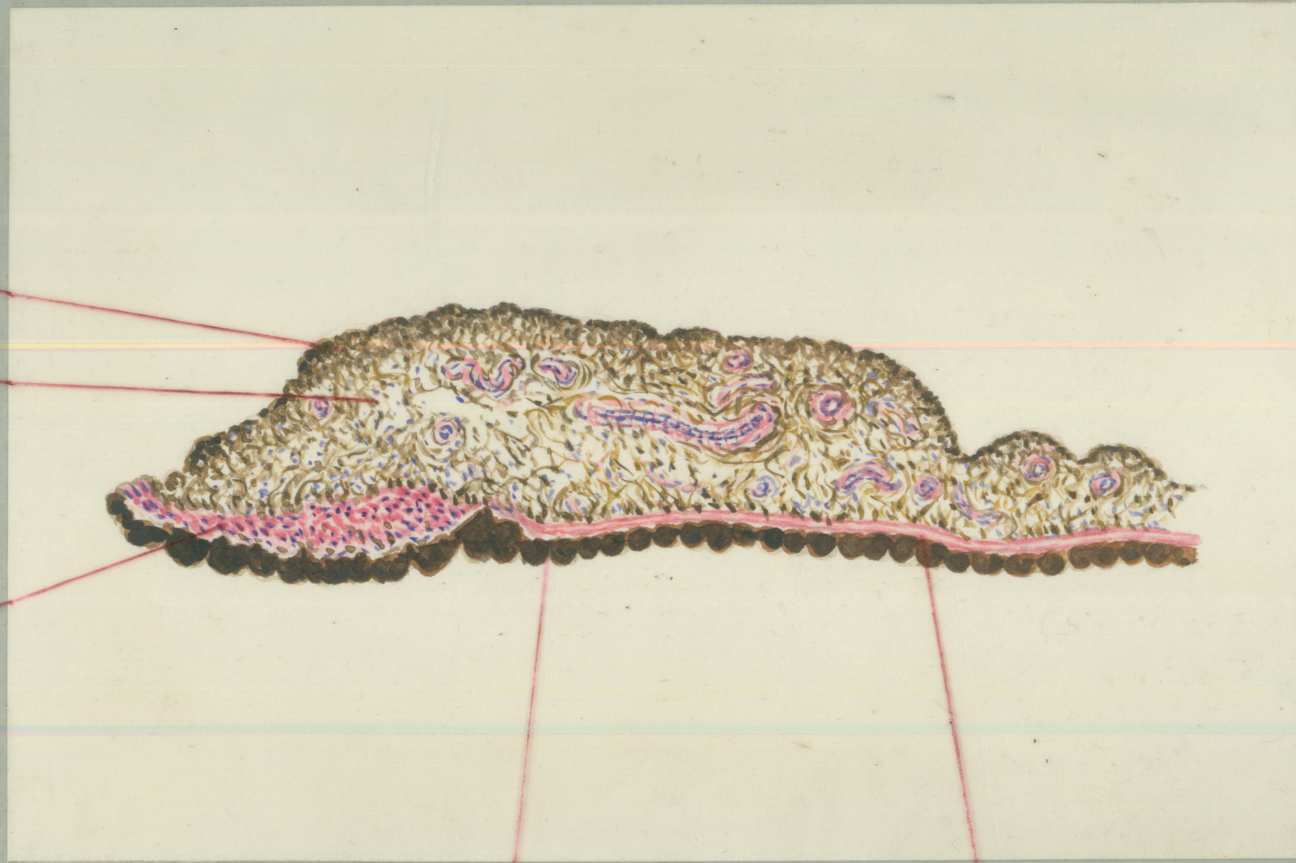
Iris, human. HX-E. (meridional section)

Stroma iridis

Anterior border layer

Vessel layer

M. sphincter pupillae



Pars iridica retinae

Posterior border layer (M. dilatator pupillae)

虹彩 (人)

HX-E 染色

x 50

7