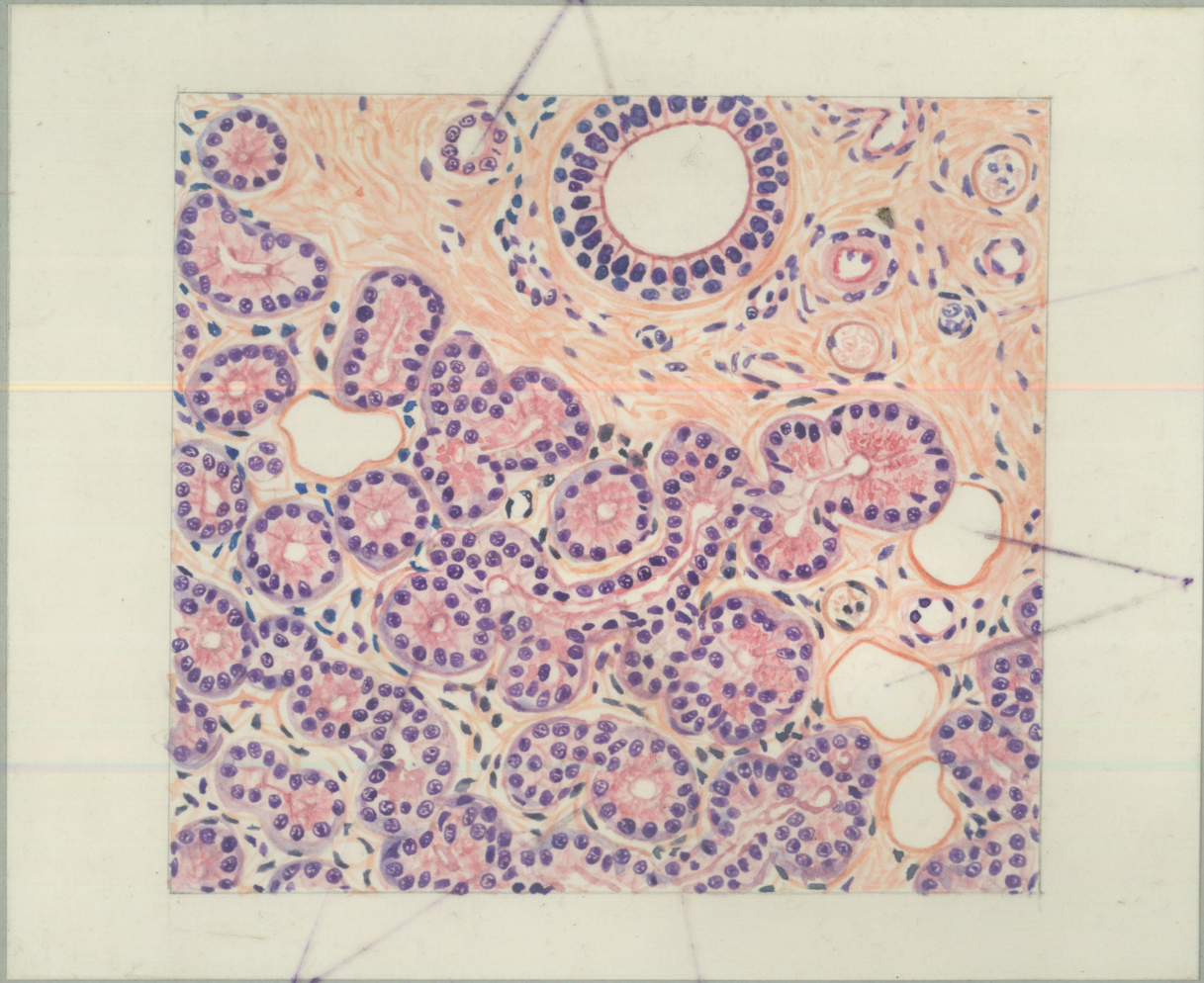


NUM-Lp002-222

A small lobule of lacrimal gland, human, HX-E.

Excretory ducts



Fat cells

淚腺 (人) HX-E 染色 x 200

4