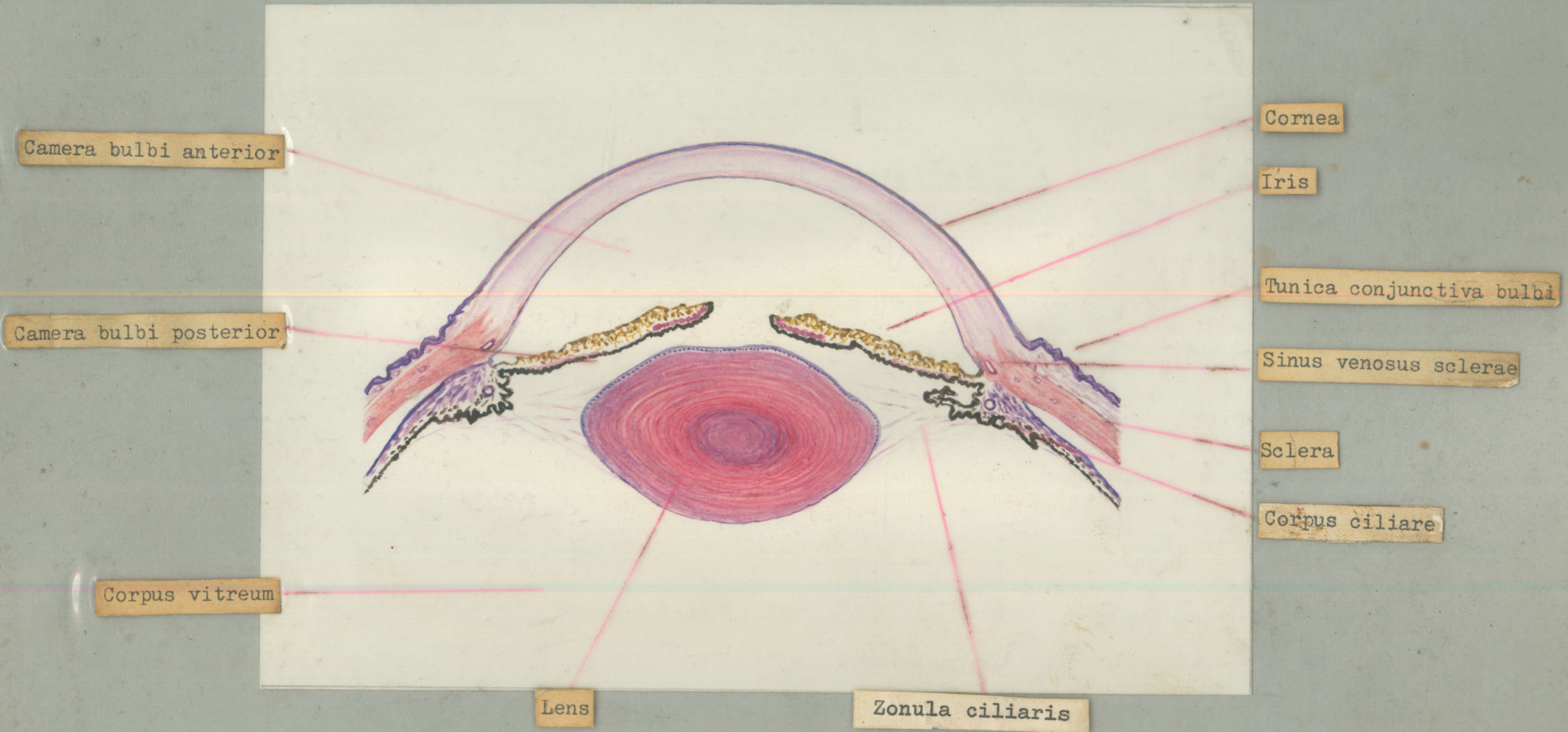


NUM-Lp002-217

Anterior portion of eye-ball, human. HX-E. (horizontal section)



眼球前部 (人) HX-E染色

X 10



1